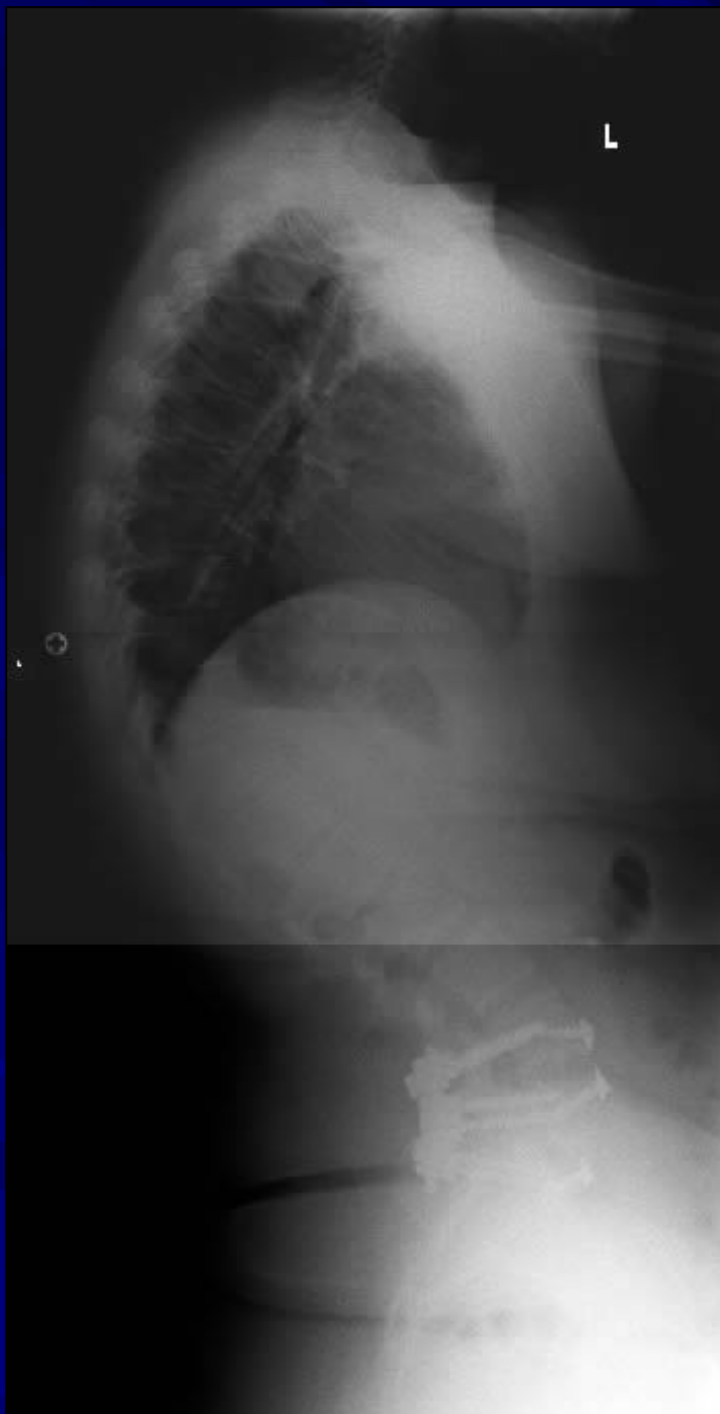



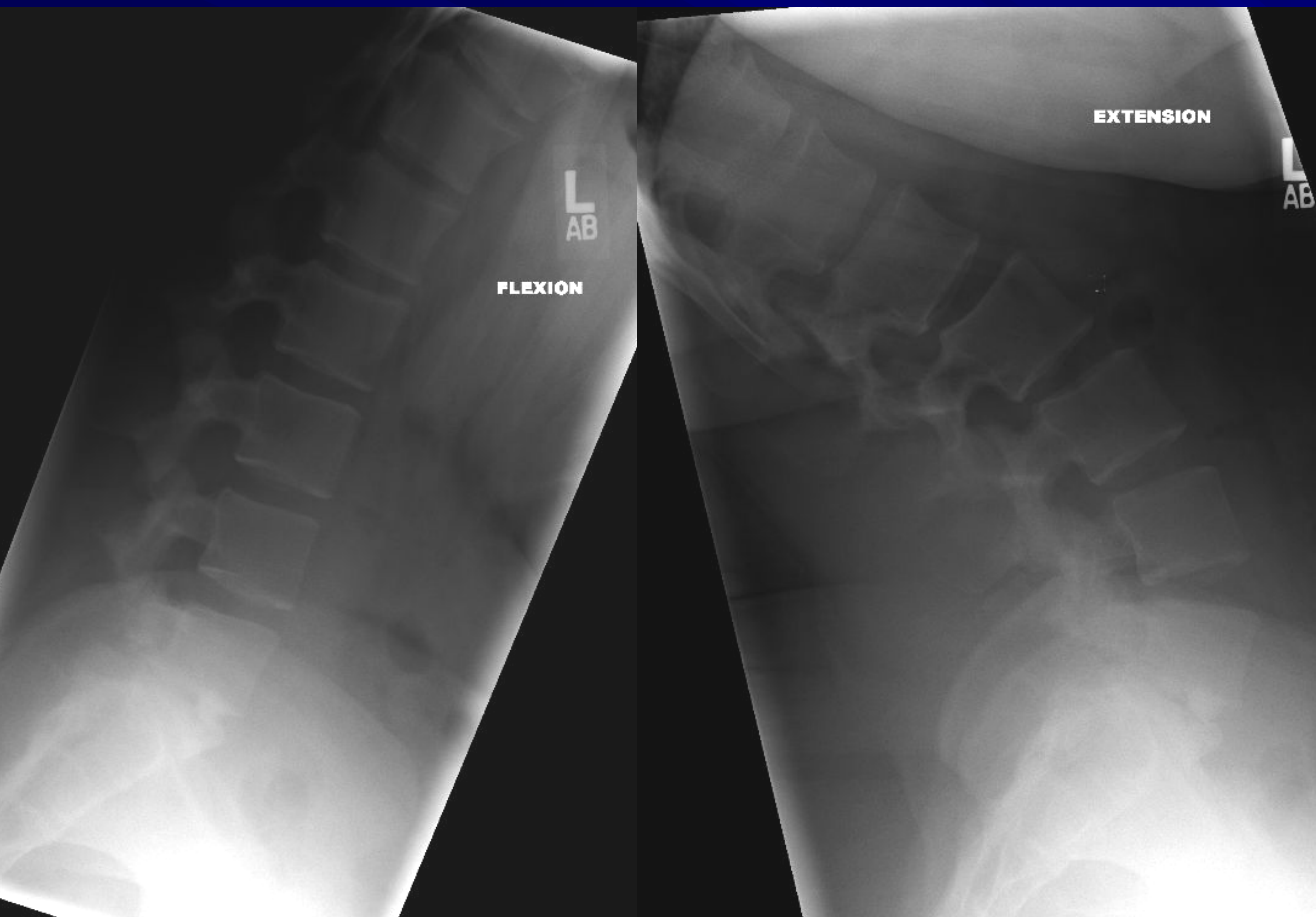## Case Review: Schuermann's Kyphosis

**Robert S Pashman, MD**  
Scoliosis and Spinal Deformity Surgery  
[www.eSpine.com](http://www.eSpine.com)

# Patient History

- 19 year old female presented with Scheuermann's kyphosis, 80°.
- Status post anterior/posterior spinal fusion, L4-S1.
- Isthmic spondylolisthesis.
- Co-morbidity, including overweight and narcotic usage.

# Indications for Surgery

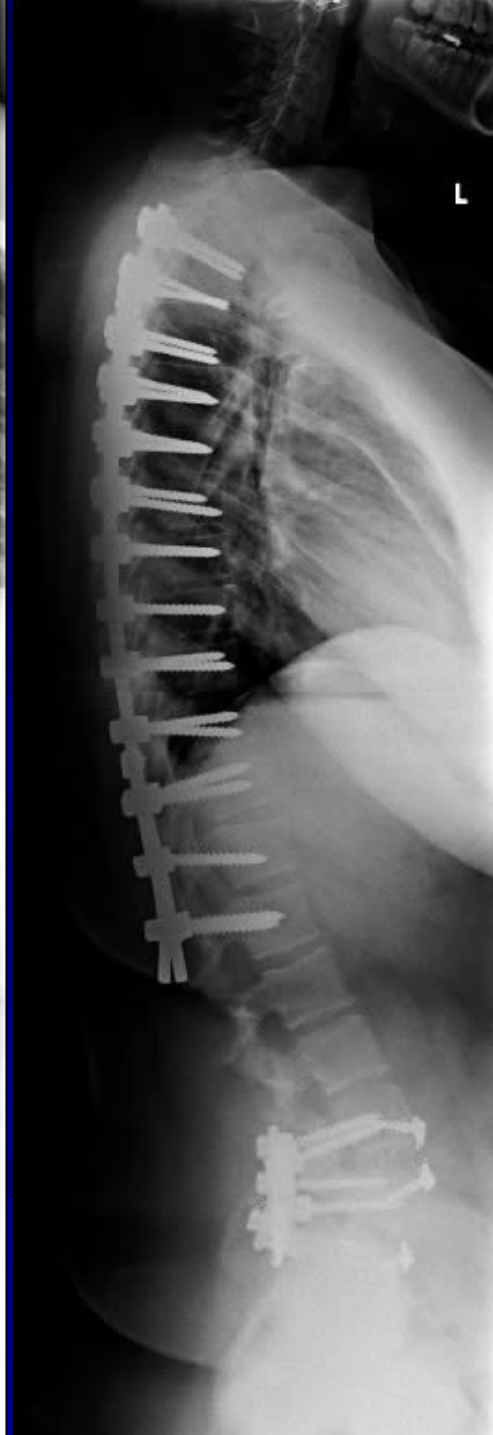
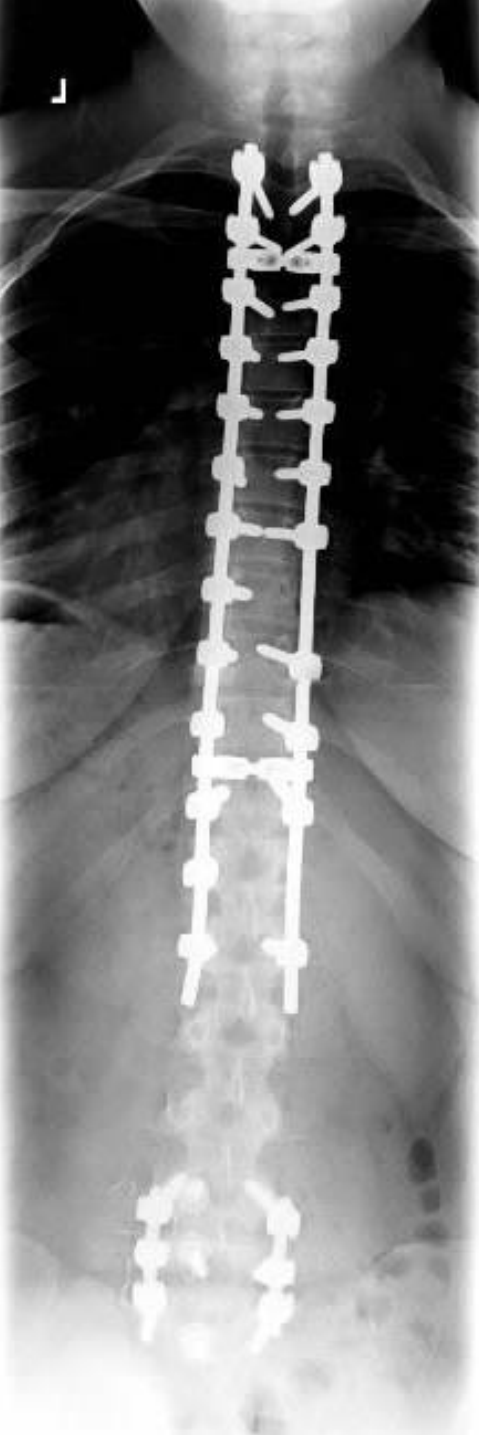

- This is not a flexible curve. She has significant pain in her neck and low back from the curvature.
- Significant cosmetic deformity
- Failed conservative therapy
- Pseudoarthrosis

# Surgical Strategy

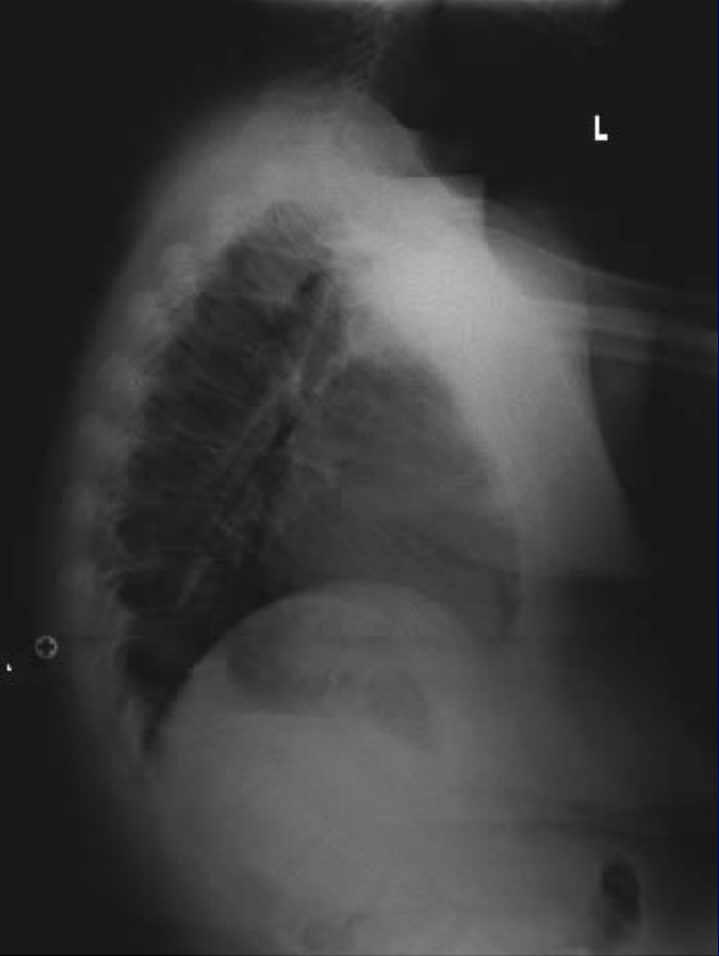
- Segmental spinal instrumentation, thoracic 2 to lumbar 1. This is a 13-level fusion with pedicle screw thoracic 5.5 stainless steel rod construct.
- Posterior spinal fusion, thoracic 2 to L1, using combination of locally harvested autogenous bone and putty extender.
- Osteotomy for mobilization of spine posteriorly, T4, T5, T6, T7, T8, T9. These are bilateral facetectomies and osteotomies through ankylosed spine with Scheuermann's kyphosis.
- Intraoperative somatosensory evoked potentials.
- Intraoperative fluoroscopy.
- Plastic closure of wound.

# Post-Op X-Rays

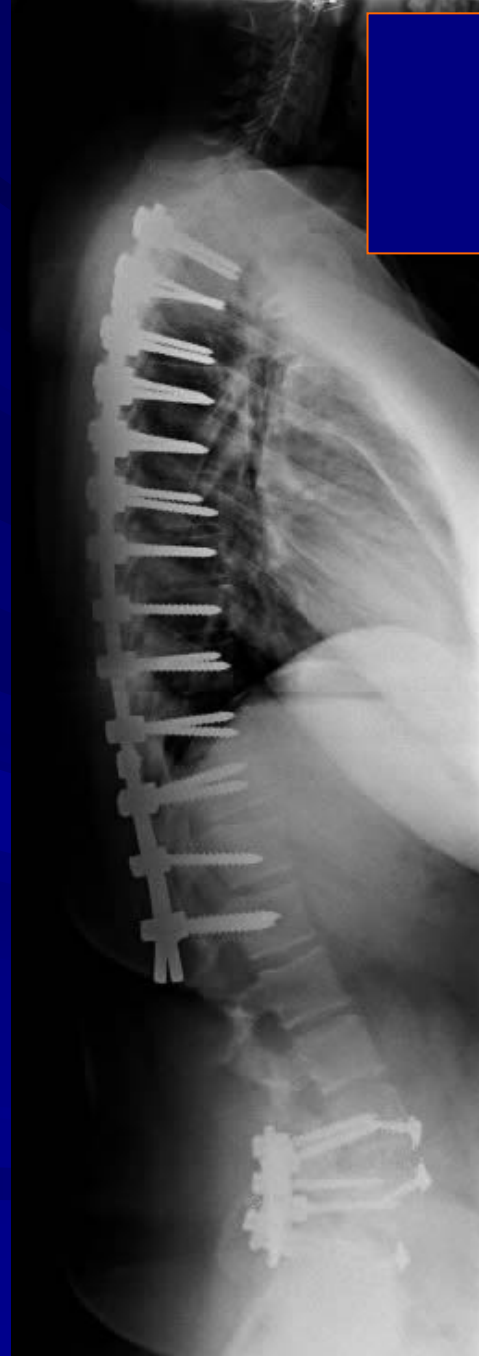


# Post-Op x-rays Comparison

The patient is well balanced in her frontal and sagittal plane. She has some low back pain. She is continuing physical therapy exercises, and has lost weight.



November 2006



January 2007