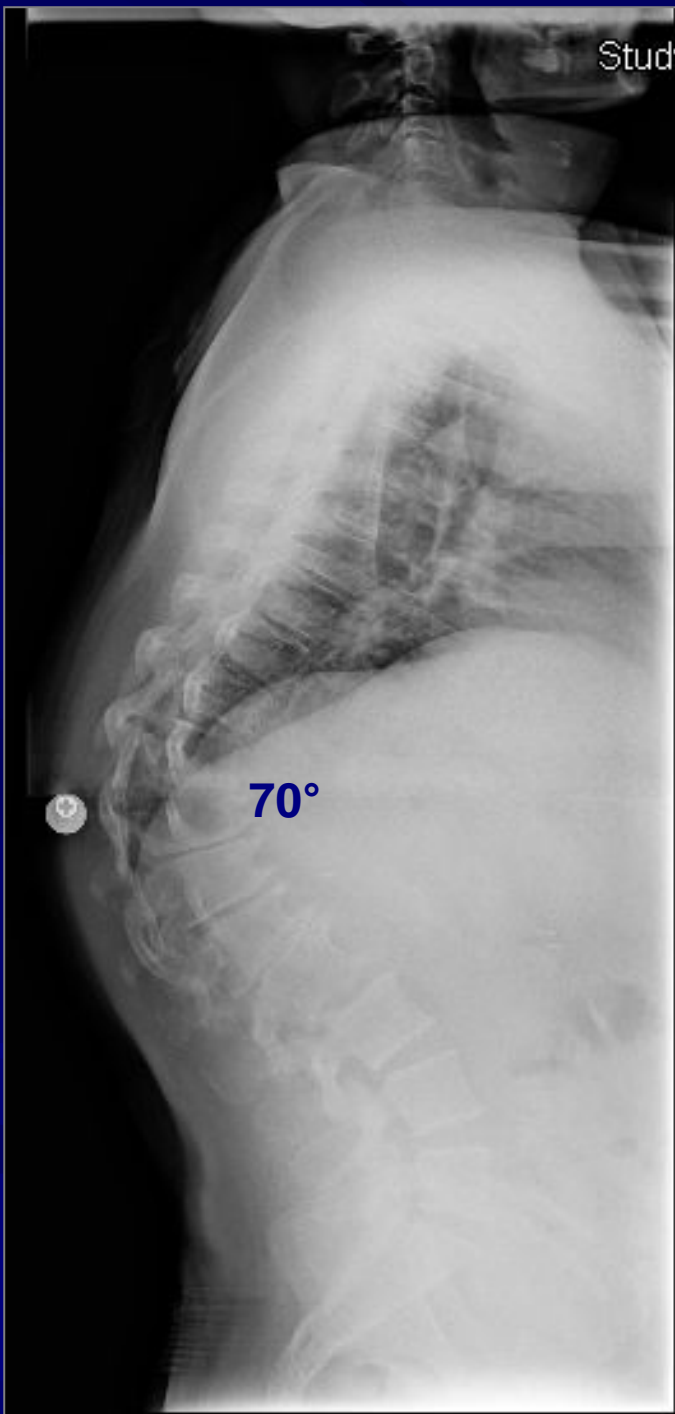

Case Review:

70° Rigid Scheurmann's
Kyphosis Treated with a
Posterior Spinal Fusion
from T2-L4.

Robert S Pashman, MD

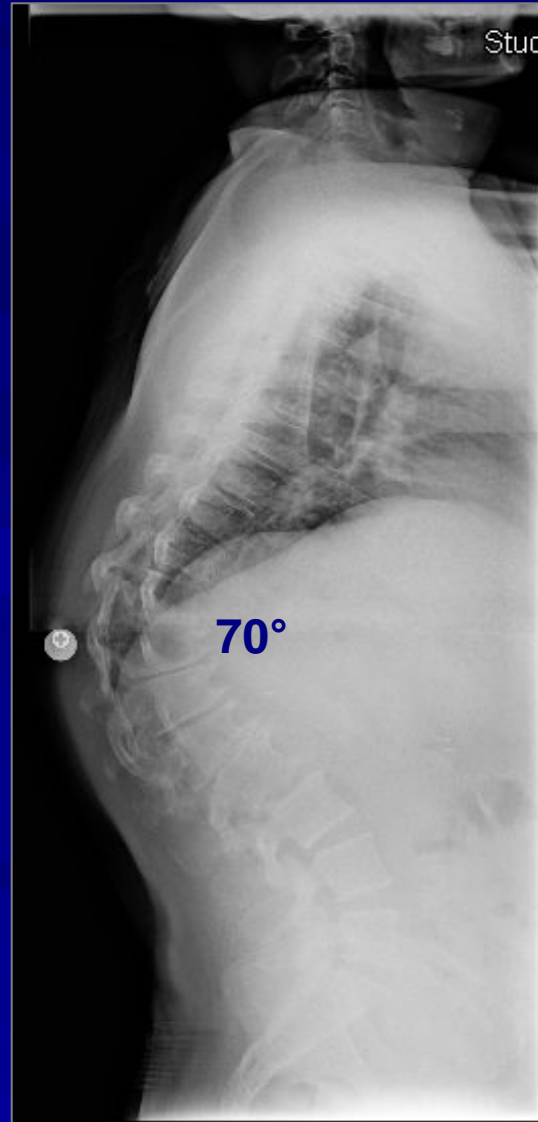
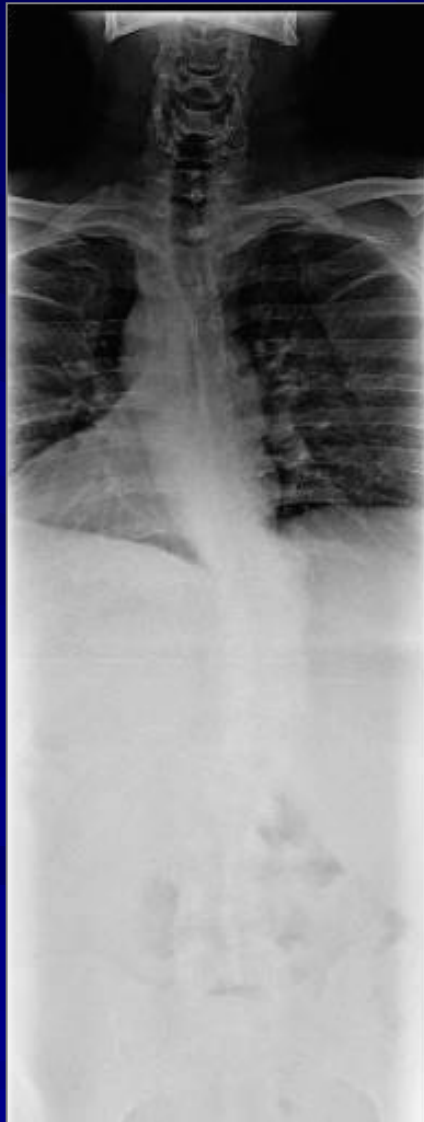Scoliosis and Spinal Deformity Surgery

www.eSpine.com

Patient History

- 48-year-old Egyptian man
- Rigid thick type 2 Scheuermann kyphosis of the thoracolumbar spine measuring 70° .
- The patient has hypercompensatory lordosis, thoracic hypercompensatory lordosis of lumbar spine, both causing significant symptoms referable to this area.
- The hyperlordosis of the lumbar spine causes significant foraminal stenosis as the spine is drawn into compression. This all needed to be decompressed.

Pre-op X-rays



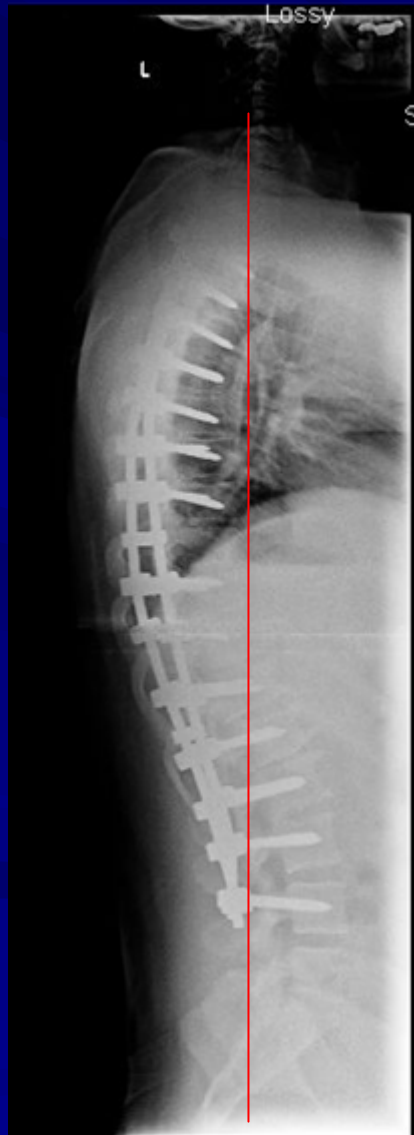
Indications for Surgery

1. Rigid Scheuermann kyphosis thoracolumbar type 2, 70-degree fixed apical T10 abnormality.
2. Incidental scoliosis thoracolumbar spine.
3. Severe low back pain and radiculopathy due to kyphosis and compensatory hyperlordosis of lumbar spine.
4. Multiple co-morbidities including type 2 diabetes and chronic smoking.
5. Now with inability to function due to pain and chronic congestion due to smoking and pulmonary compression, status post cardiac stent.

Surgical Strategy

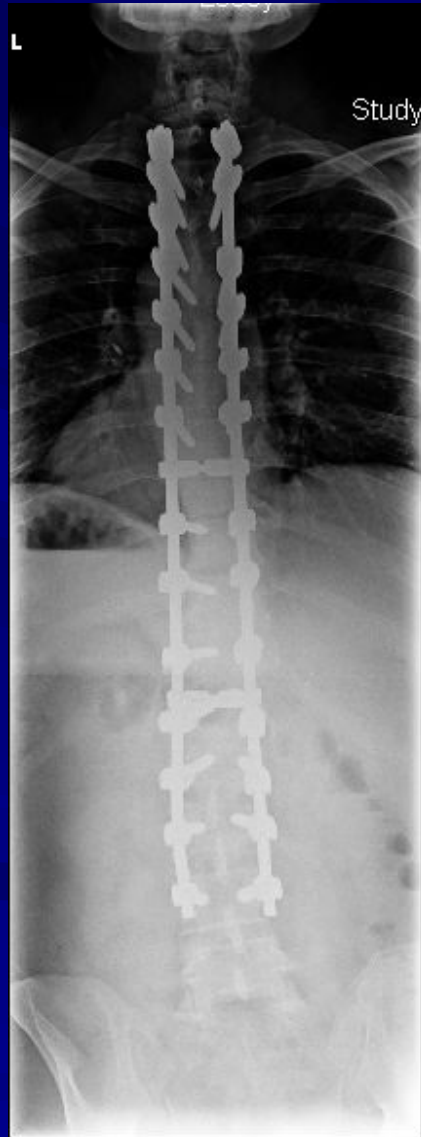
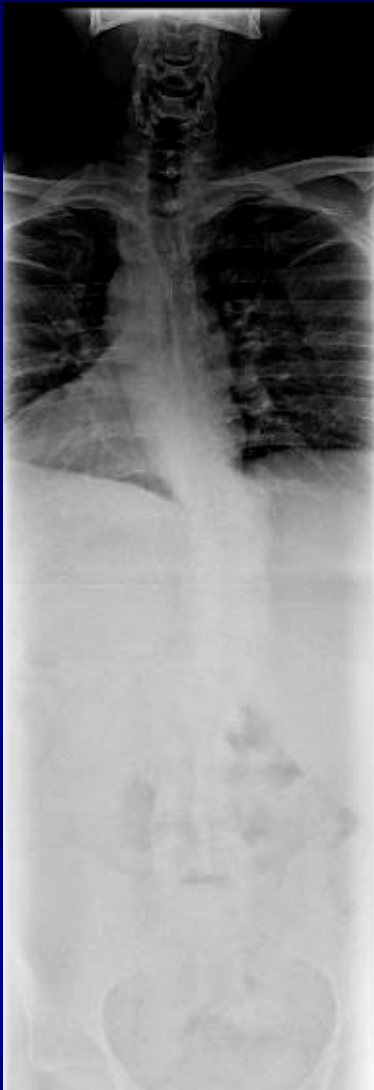
- Thoracic 2 to lumbar 4 posterior instrumented fusion with 1/4-inch stainless steel Legacy pedicle screw rod construction, this is 16 levels.
- Posterior spinal fusion T2 to L4. This is a 16 level posterior spinal fusion with the combination of locally harvested autogenous bone and Rh bone morphogenic protein.
- Spinal osteotomy Smith-P/Ponte radical facetectomy for posterior release of thoracolumbar spine T7-8, T8-9, T9-10, T10-11, T11-12 and L1-L2. This is a 6 level osteotomy.
- Subtotal laminectomy for decompression of spinal cord over kyphotic segments T7-8 to L1-2. This is a 6 level spinal decompression with the microscope.
- Interlaminar laminotomy, mesial facetectomy, lateral release for spinal stenosis due to hyperlordotic compensatory lumbar spine L1-2, L2-3, L3-4, L4-5, all under the microscope.
- Motor evoked potentials, somatosensory evoked potentials.
- Intraoperative fluoroscopy.

Post-Op Films



The patient is well balanced in both the sagittal and coronal planes.

Pre-Op/Post-op Comparison



Pre-Op/Post-op Comparison

