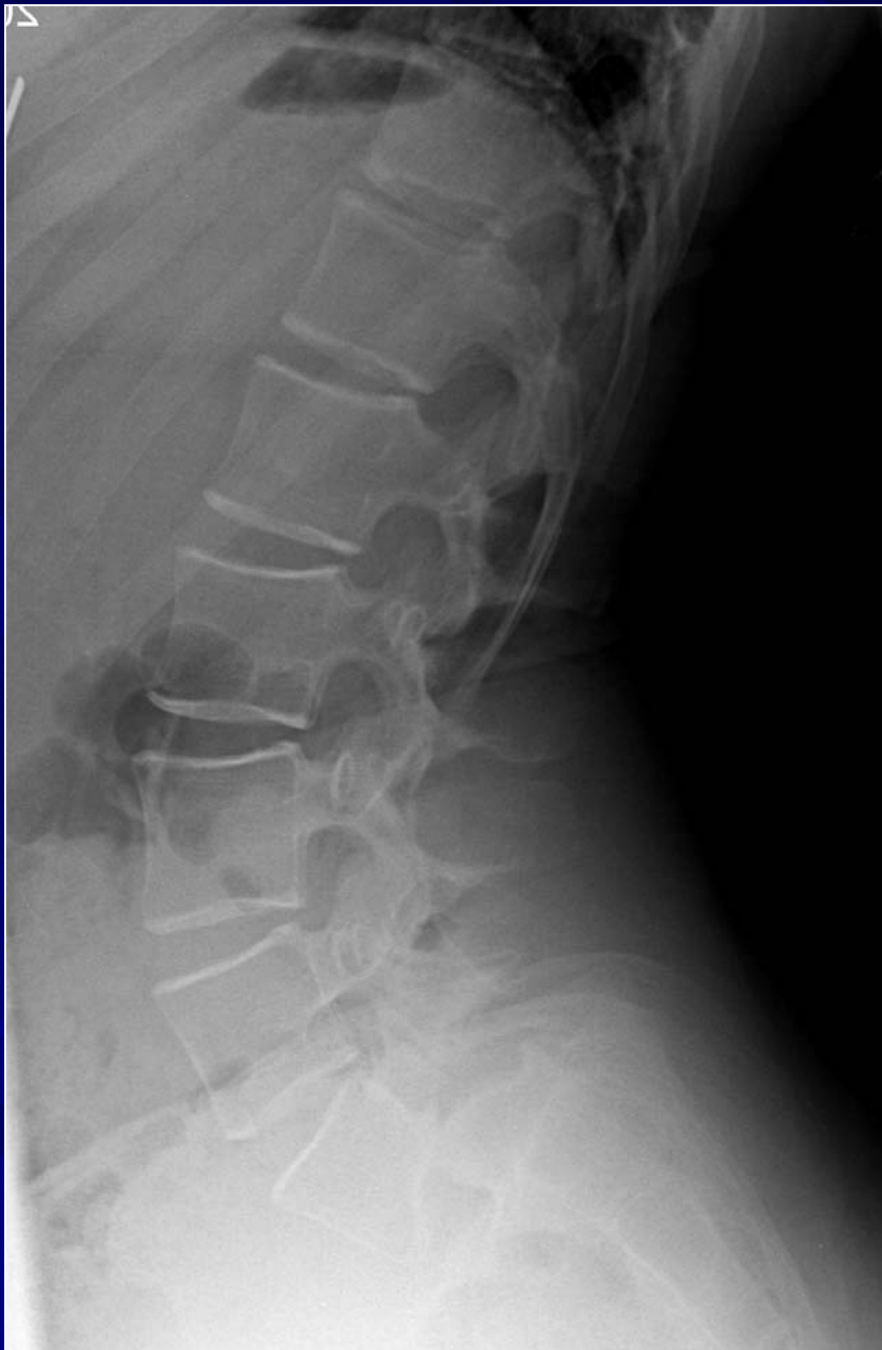



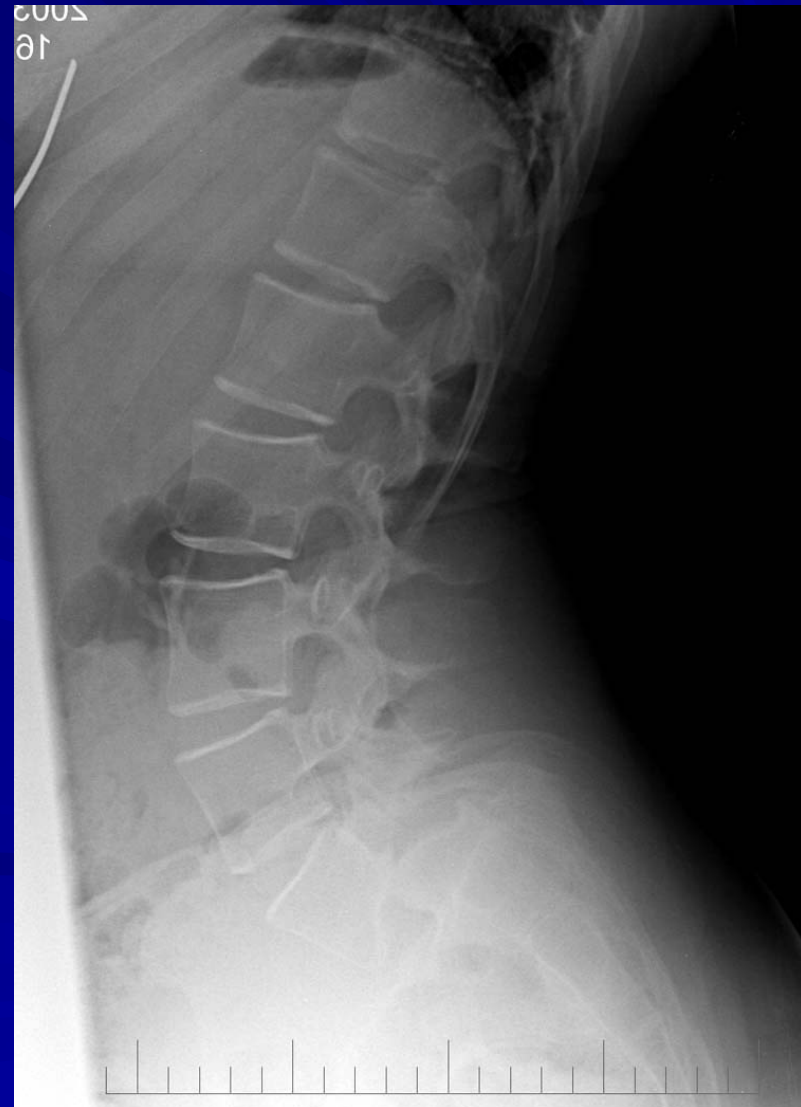Isthmic Spondylolisthesis Grade IV:

Treated with an
anterior and posterior
spinal fusion

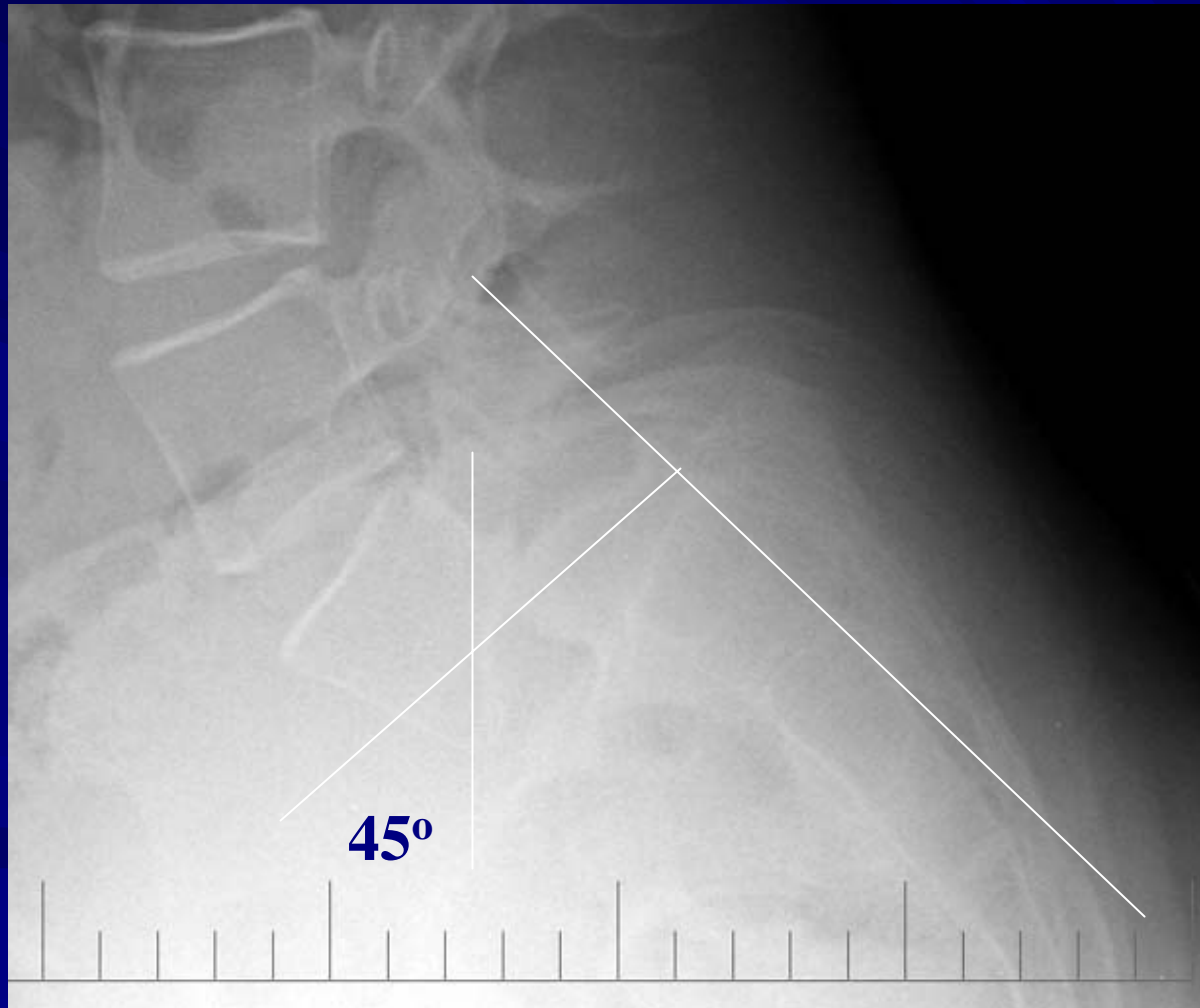
Robert S Pashman, MD
Scoliosis and Spinal Deformity Surgery
www.eSpine.com

Grade IV Isthmic Spondylolisthesis

- 16 year old female
- Documented progression of Spondylolisthesis from 2002 to 2003
- L5 weakness of left foot
- Low back and leg pain



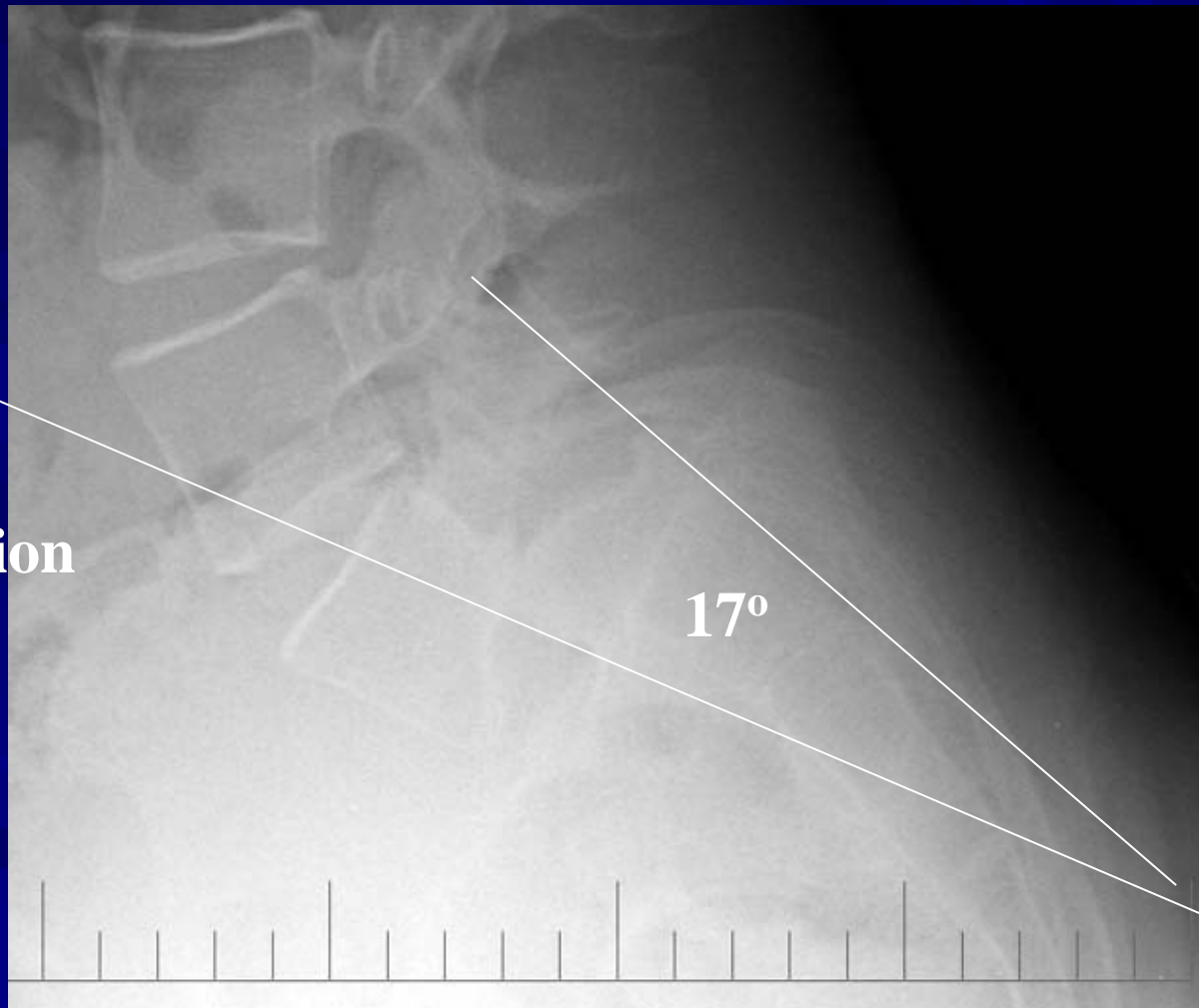
Slip Angle



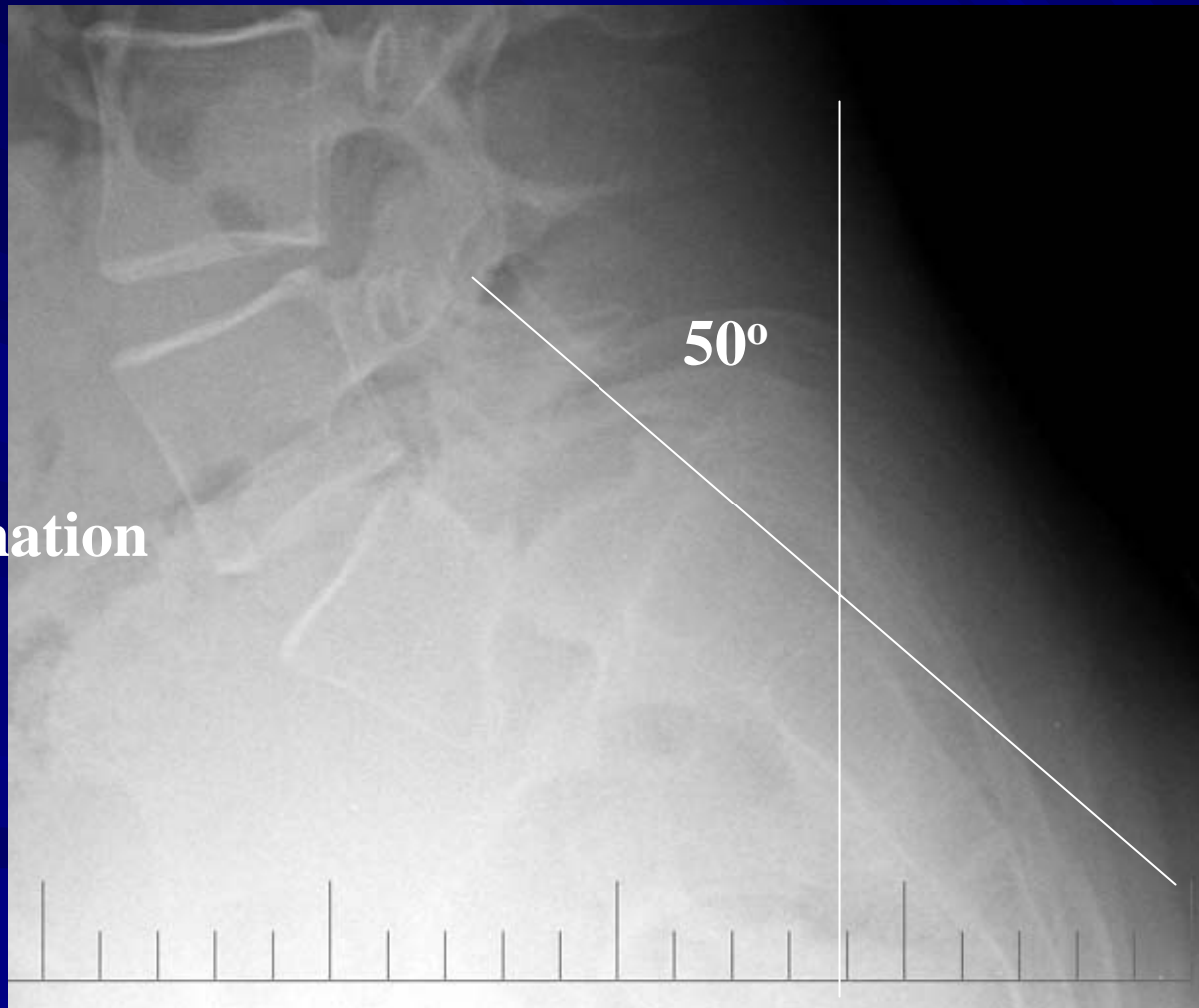
Slip Angle

Sagittal Rotation

Sagittal Rotation



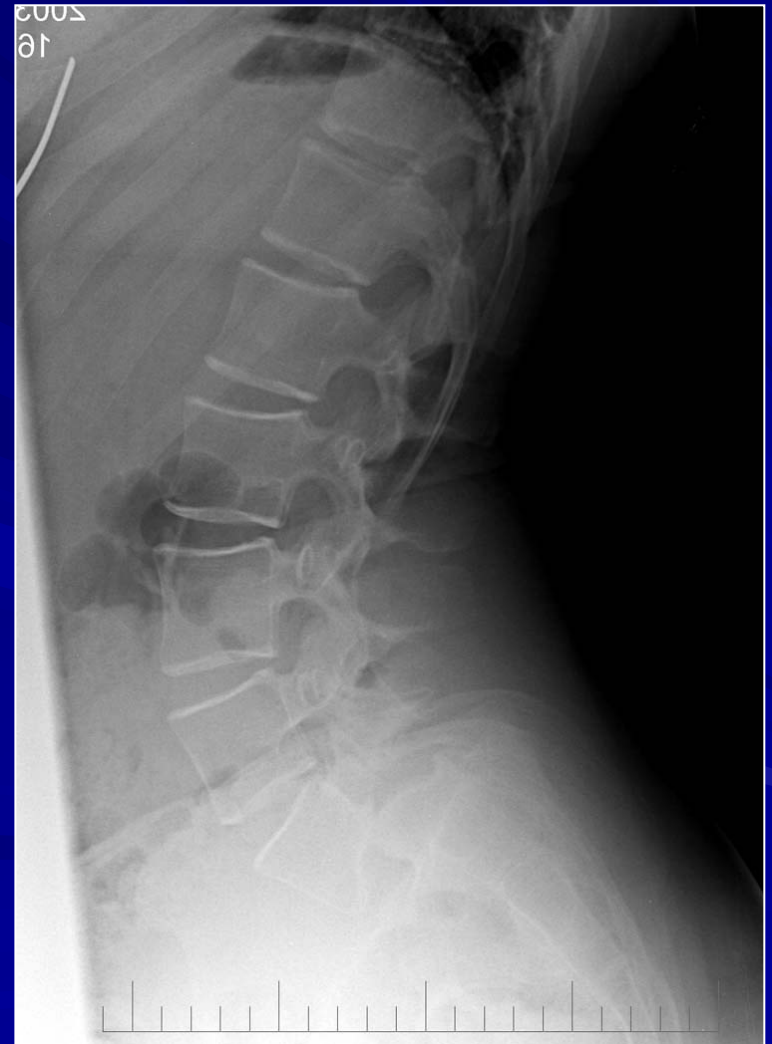Sacral Inclination



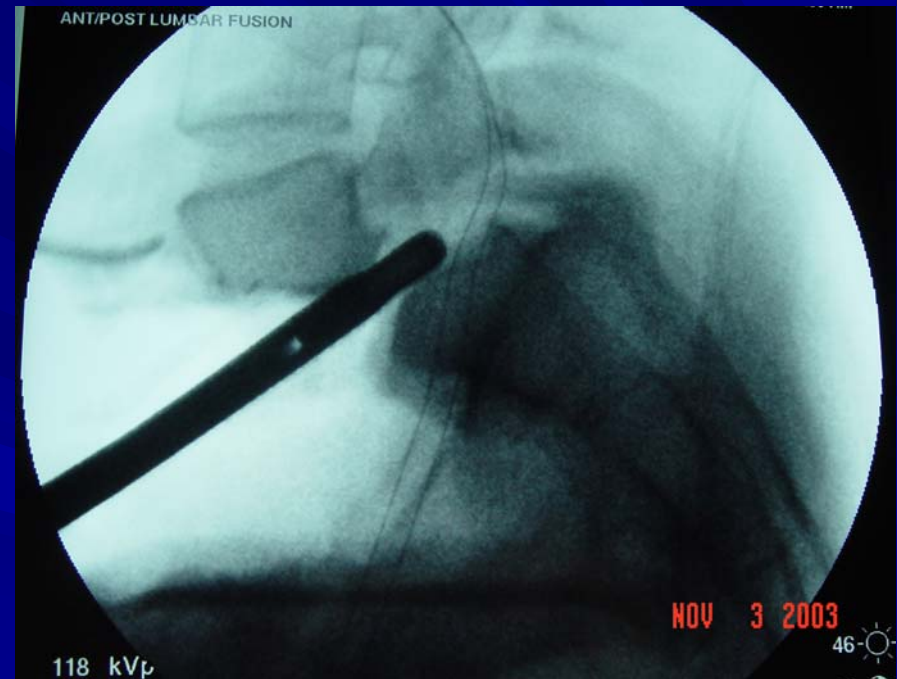
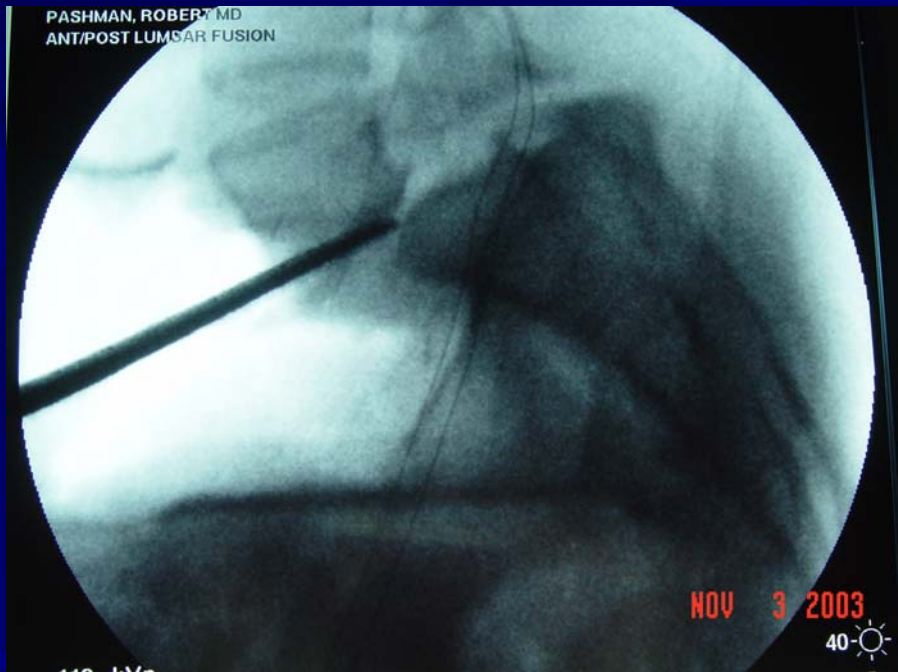
Sacral Inclination

Surgical Plan

- Laminectomy L5
- Bilateral foraminotomy L5-S1
- L5-S1 Microdisectomy
- Spondylolisthesis reduction
- Anterior interbody fusion at L4-S1
- Posterior fusion L4-S1

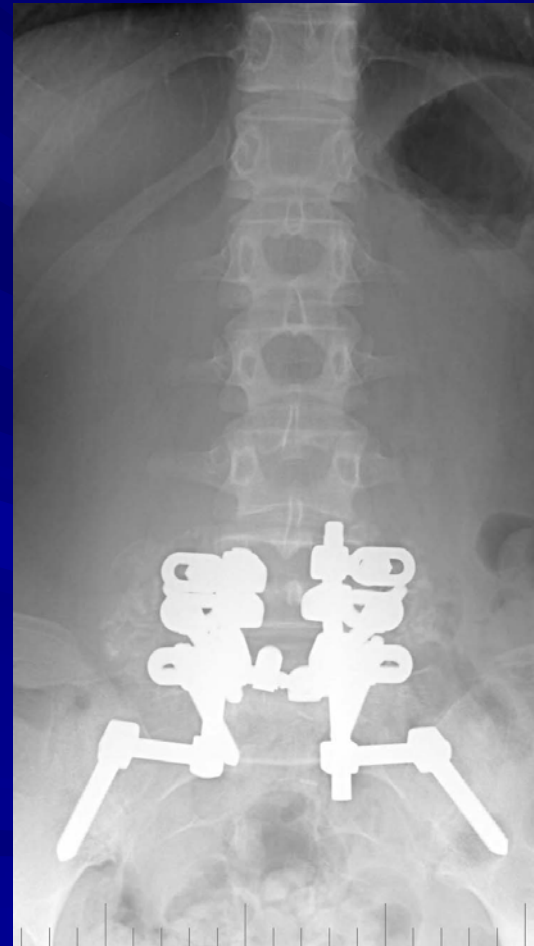
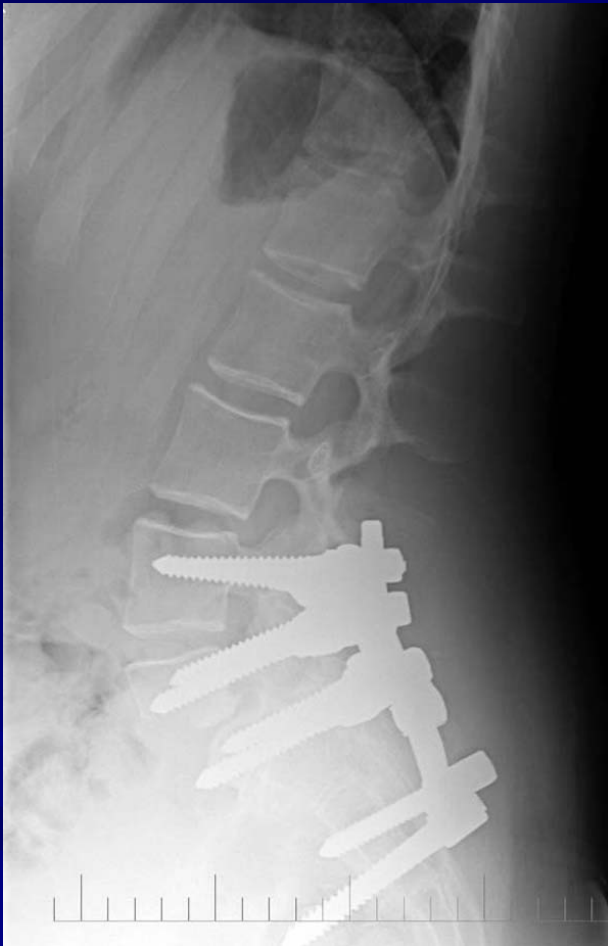
Surgical Treatment



ASF Subtotal Vertebrectomy and Reduction

Post Surgery



The patient's symptoms were resolved following surgery.