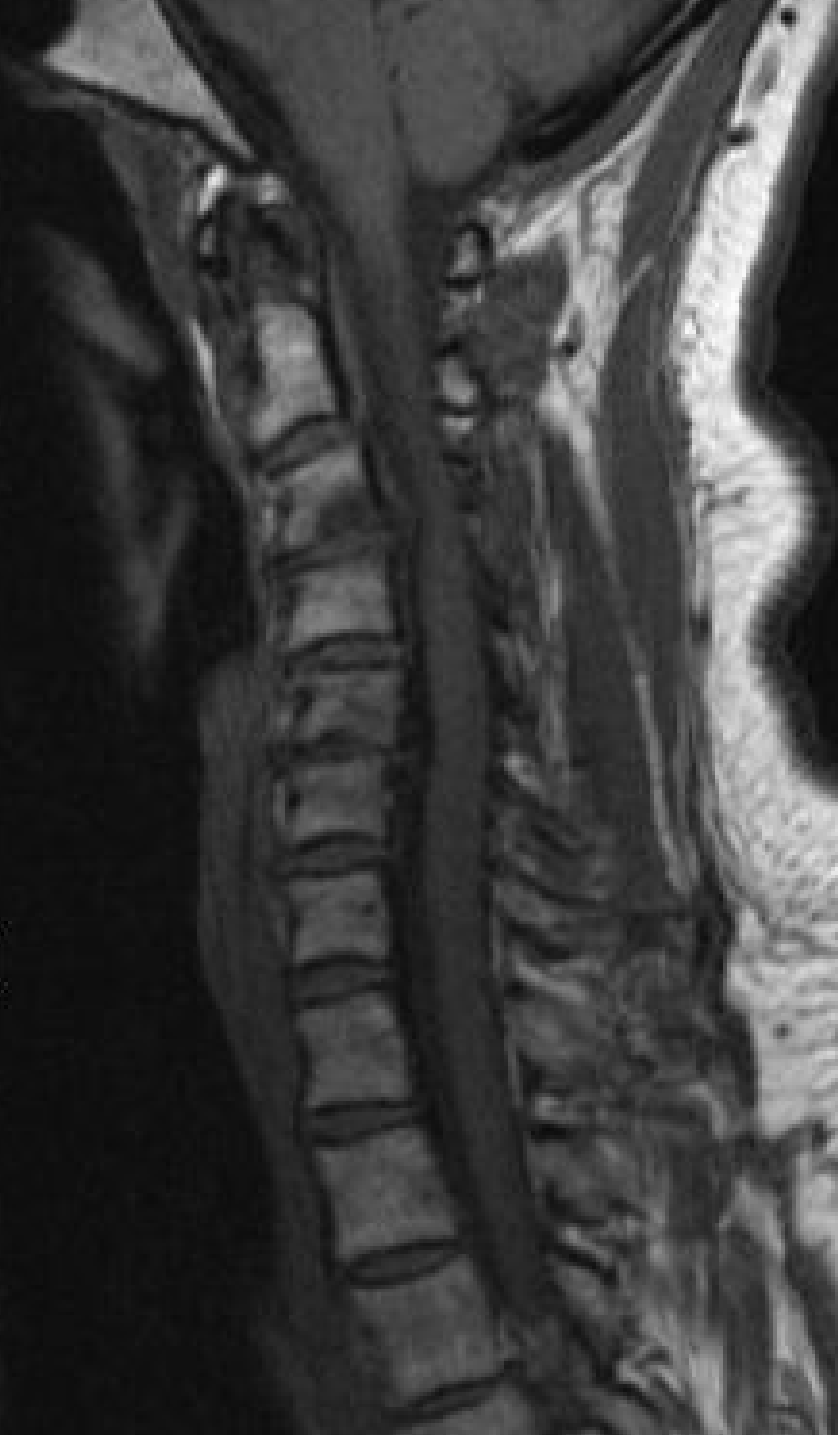



Case Review:

57 year old female with
massive spinal cord
compression C3-7

Robert S Pashman, MD

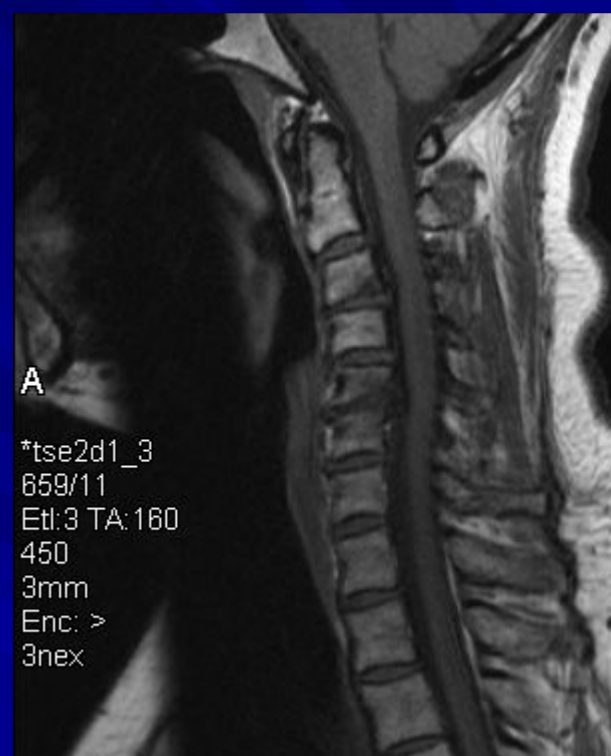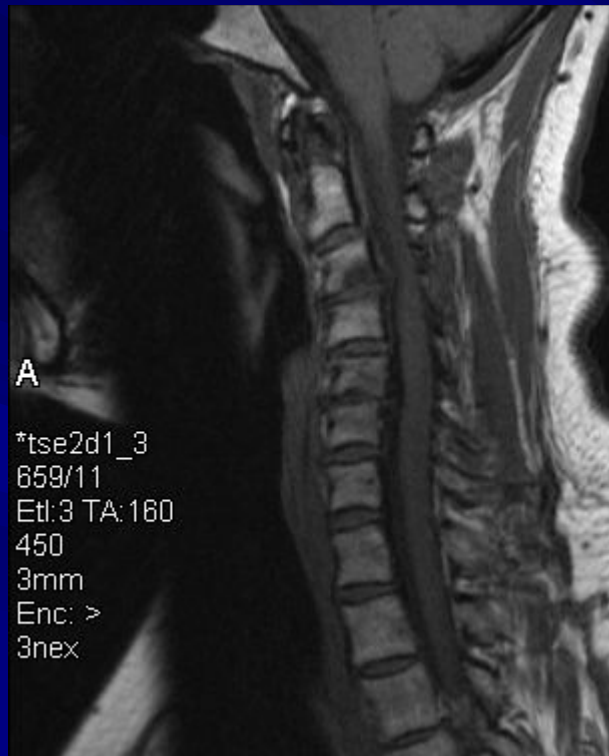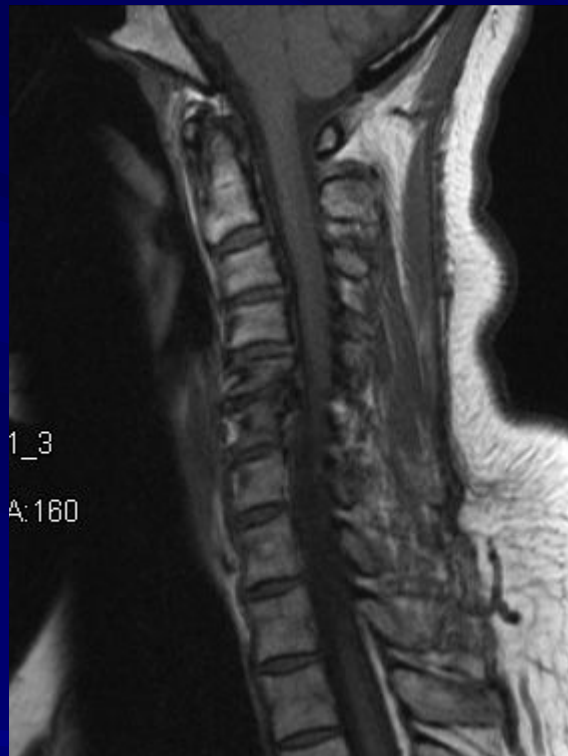Scoliosis and Spinal Deformity Surgery

www.eSpine.com

Patient History

- 57-year-old female.
- Massive spinal cord compression behind C3-4 with cervical kyphosis.
- Junctional kyphosis at C5-6 with massive neural foraminal stenosis.
- Degenerative Disk Disease at C4-5.
- Broad-based disk herniation at C6-7.
- Neck stiffness, pain and numbness in the hands and intermittent symptoms that are running down into her legs.
- Patient failed conservative treatment.
- Patient obtained multiple surgical opinions.

Pre-op Films



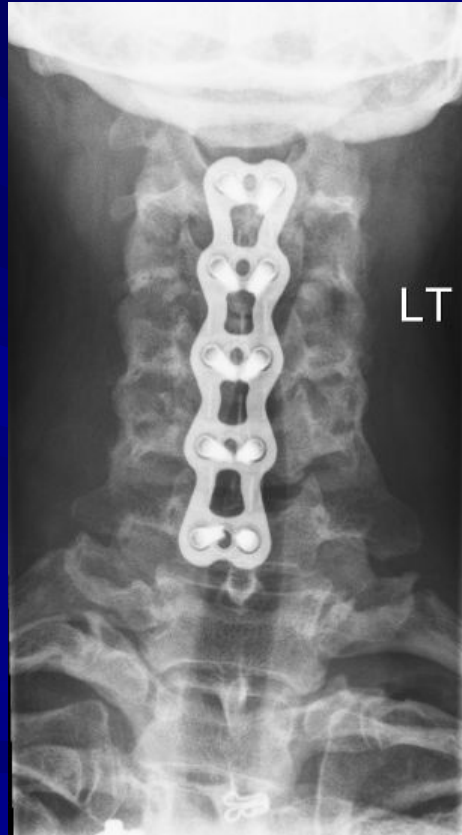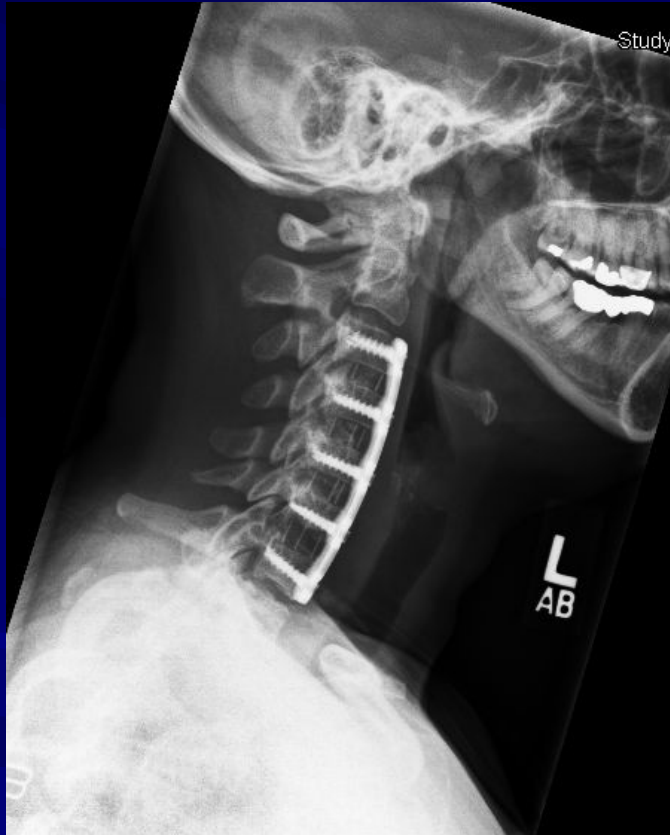
Indications for Surgery

1. Mass with spinal cord compression, C3-4, 4-5, 5-6 and 6-7.
2. Cervical kyphosis, C3-4, 4-5, 5-6 and 6-7.
3. Intermittent neurologic symptoms and weakness with left-sided pain and intermittent right-sided pain and radicular nature.
4. Myelopathy with intermittent upper motor neuron signs due to spinal cord compression.
5. Failed conservative therapy.
6. Increasing symptoms with myeloradicular symptoms.

Surgical Strategy

- Radical diskectomy, C3-4, C4-5, C5-6 and C6-7 under the microscope with epidural compression and spinal cord decompression, bilateral neural foraminal decompression.
- Interbody fusion with PEEK device, C4-5, C4-5, C5-6 and C6-7 with autogenous bone centrally from the uncovertebral osteophyctomy.
- Subtotal vertebrectomy, C4, C5 and C6 with removal of anterior posterior uncovertebral osteophyte constituting one-third vertebrectomy for myelopathy, spinal stenosis and cervical kyphosis.
- Anterior cervical plate fixation using a 10-hole Atlantis Vantage plate, C3-C7.
- Intraoperative somatosensory-evoked potentials.
- Intraoperative fluoroscopy management.

Post-Op Films



Her neck and arm symptoms had completely resolved after surgery. Her hardware and grafts are all in good position, with good cervical lordosis obtained, and good alignment of her cervical spine.