

# **Flatback Syndrome treated with ASF/PSF**

**Robert S. Pashman, MD**

---

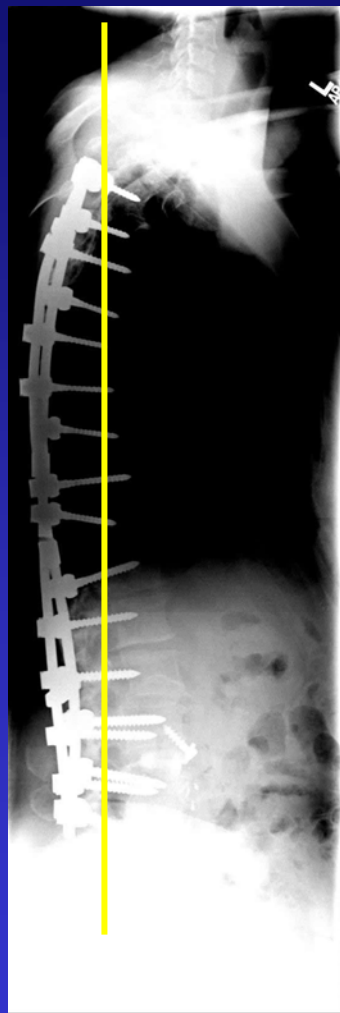
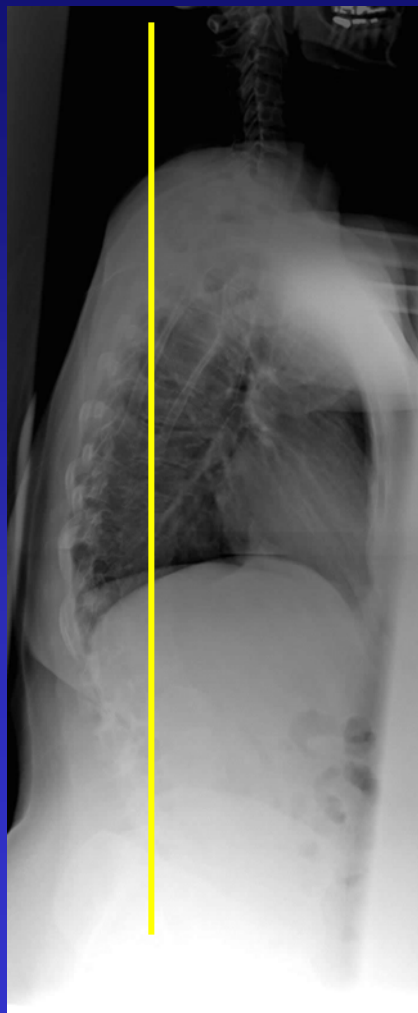
---

**Scoliosis and Spinal Deformity Surgery**  
**[www.eSpine.com](http://www.eSpine.com)**

# Flatback Syndrome

- 48 year old female with Adult Idiopathic Scoliosis
- 1 year status post Anterior/Posterior Spinal Fusion to correct 60° thoracolumbar-lumbar curvature
- Progressive decompensation forward
- Low back pain
- Failed conservative therapy

# Pre-Operative X-Rays

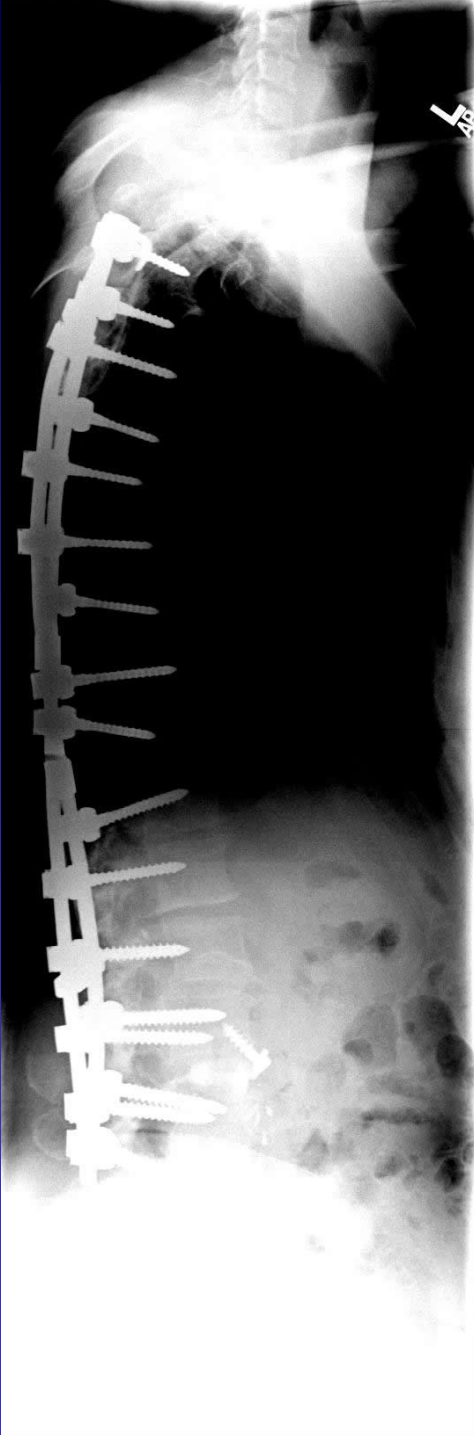


The patient presented with low back and leg pain.

Patient is decompensated forward as shown with plumbline. There is also decreased lumbar lordosis.

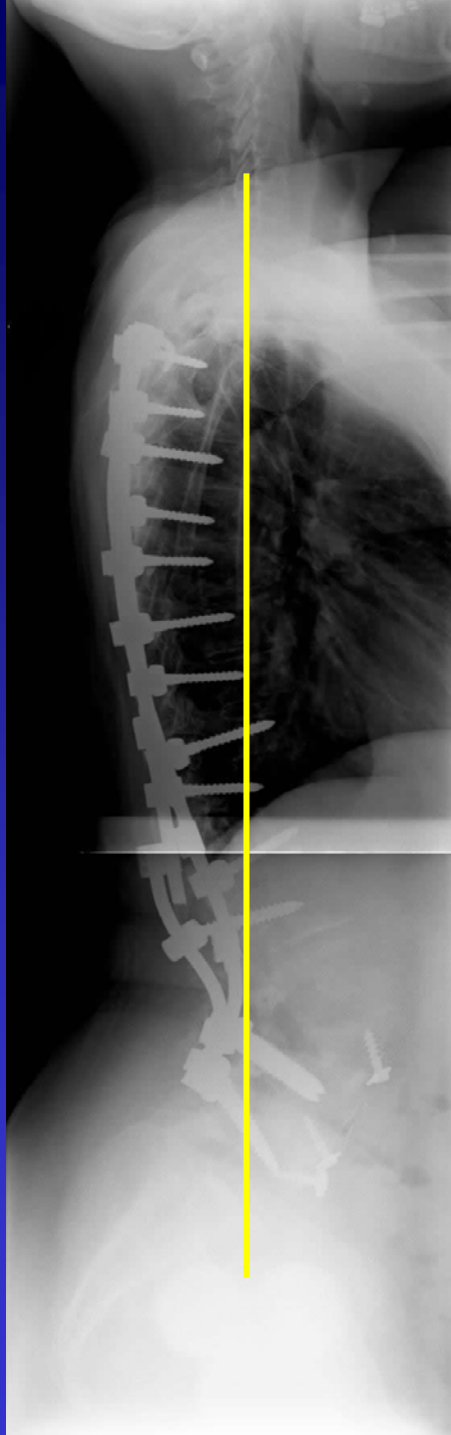
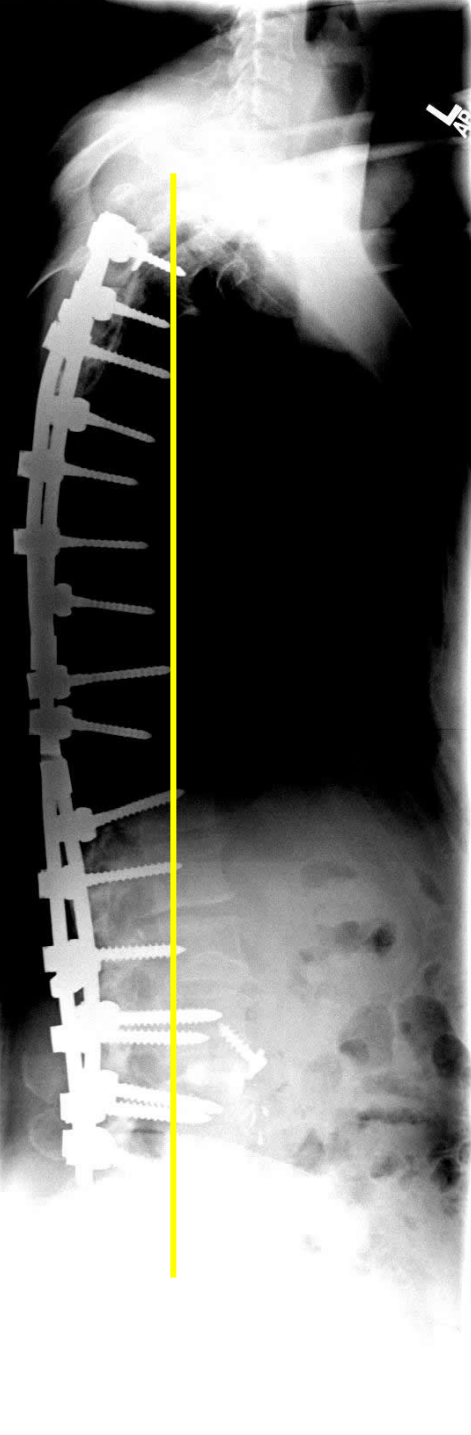
**Pre-op**

**Pre-Flatback  
correction surgery**



# Surgical Strategy

- Kyphectomy L3
- Laminectomy L3, subtotal laminectomy L2 and L4
- Decancellation osteotomy, pedicle subtraction osteotomy L3
- Spinal instrumentation T12-L5
- Posterior lateral intertransverse fusion T12-L5



# Results

- Sagittal balance was corrected.
- Lumbar lordosis was induced.
- The patient now plumb line's perfectly.
- The patient's symptoms were resolved.